# Processes Petrolingualis of the Foramen Lacerum and Relationship with the Internal Carotid Artery

# Foramen Laserum'um Petrolingual Çıkıntısı ve Internal Carotid Arter ile İlişkisi

Volume Rendering Anatomy of the Processes Petrolingualis

Enis Kuruoglu
Department of Neurosurgery, Ondokuz Mayis University, Medical Faculty, Samsun, Türkiye

**Özet**

Petrolingual ligamentin üst sınırı, lacerum kısımdan internal karotid arterin kavernöz kısmının belirlenmesi için bir göstergedir. intrakranial anevrizmaların varlığını veya yokluğunu değerlendirmek için, bu çalışmaya dahil edilen hastalar bilgisayarlı tomografik anjiografi ile değerlendirildi. Görüntüleme verileri tıp (DICOM) formatında dijital görüntüleme için saklanmış ve ardından üç boyutlu görüntüleri nörovasküler görüntülere dönüştürmek için görüntüleme yazılımı ile analiz edilmiştir. 54 hastanın (27 erkek ve 27 kadın) nörovasküler görüntülerinden oluşturulan üç boyutlu hacim görüntüleri petrolingual çıkıntıyı analiz etmek için değerlendirildi. Tüm olgularda, petrolingual çıkıntı iç (temporal kemiğin petrous kısmı) ve yan (sfenoid kemik) tarafından belirlenmiştir. Bu kemik çıkıntı üç boyutlu bilgisayarlı tomografik anjiyografi yapılan hastalarda internal karotid arter sınıflandırılmasında kullanılabilir. Bu çalışmada, çıkıntının şekli ve onun karotid arter ile ilişkisi tanımlanmıştır.

**Anahtar Kelimeler**

Petrolingual Çıkıntı; Karotid Kanal; Karotid Foramen; Hacim Rendering Tekniği; Mikrocerrahi Anatomi; Üç Boyutlu Görüntüler; Bilgisayarlı Tomografi

**Abstract**

The superior border of the petrolingual ligament is the marker for differentiating the cavernous part of the internal carotid artery from the lacerum part. To evaluate the presence or absence of intracranial aneurysms, the patients included in this study were evaluated with computerized tomographic angiography. Imaging data were stored in digital imaging and communications in medicine (DICOM) format and subsequently converted using imaging software into three-dimensional volume rendered neurovascular images. These images of the 54 patients (27 male and 27 female) were evaluated to analyze the processes of the petrolingualis. In all cases, the processes of the petrolingualis were determined on the medial (petrous portion of the temporal bone) and lateral (sphenoid bone) side. This bony process may be used in the classification of internal carotid artery in patients who underwent three-dimensional computerized tomographic angiography. In the present study, the shape of the process and its relationship with the carotid artery were described.

**Keywords**

Processes Petrolingualis; Carotid Canal; Carotid Foramen; Volume Rendering Technique; Microsurgical Anatomy; Three-Dimensional Images; Computerized Tomography

DOI: 10.4328/JCAM.4798 Received: 03.09.2016 Accepted: 03.10.2016 Printed: 01.05.2017 J Clin Anal Med 2017;8(3): 198-201
Corresponding Author: Enis Kuruoglu, Department of Neurosurgery, Ondokuz Mayis University, Medical Faculty, 55139 Samsun, Turkey.
T.: +90 3623121919/2629 F.: +90 3624576041 E-Mail:drenis@hotmail.com

## Introduction

The foramen lacerum is different from other foramina located at the cranial base because no anatomically important neural or vascular structures pass through it. The foramen lacerum is located just inferior to the opening of the carotid canal. The internal carotid artery does not travel through the foramen lacerum. The segment of the internal carotid artery travels above the foramen lacerum. Bouthillier at al. [1] have proposed a classification system that describes the entire internal carotid artery, uses a numerical scale in the direction of blood flow, and identifies the segments of the internal carotid artery according to the anatomy surrounding the internal carotid artery and the compartments through which it travels. According to this classification, the internal carotid artery has seven segments as follows: C1, cervical; C2, petrous; C3, lacerum; C4, cavernous; C5, clinoid; C6, ophthalmic; and C7, communicating.

The internal carotid artery leaves from the carotid canal and travels above the foramen lacerum as the lacerum segment of the internal carotid artery. This segment ends at the superior border of the petrolingual ligament and enters the cavernous sinus as a cavernous segment. There is a carotid impression on the lingual part of the sphenoid bone. At the starting point of the carotid sulcus, there are two bony processes incompletely covering the sulcus. One of them is located on the petrous apex and the other is located on the sphenoid bone. The petrolingual ligament is located between the processes to cover the superior border of the internal carotid artery. The bony process located at the petrous apex is referred to as the petrous part of the processus petrolingualis, while the process located at the sphenoid bone is referred to as the sphenoid part of the processus petrolingualis.

In the present study, the shape and location of the processus petrolingualis were evaluated based on the three-dimensional volume rendered neurovascular images in order to describe their micro-vascular properties in view of the literature.

## Material and Method

To evaluate the presence or absence of intracranial aneurysms, the patients included in this study were evaluated with computerized tomographic angiography. When an aneurysm was detected, the optimal appropriate management, either surgical clipping or endovascular coiling, was chosen and offered to the patients and their families.

The images analyzed in this study were obtained using the Aquilion ONE multidetector row computerized tomography scanner (Toshiba, Medical Systems, Tokyo, Japan). All patients were given detailed instructions to lie on the table with mouth and eyes closed. A suitable external fixation device was used when necessary to stabilize the patient's head. After obtaining a frontal and lateral scanogram, a conventional unenhanced computerized tomography was performed if clinically necessary (120 kV, 200 mAs).

Computerized tomographic angiography images were acquired following intravenous timed injection of contrast agent (Visipaque [Iodixanol] 270 mg/100 ml, OPAKIM) using an auto-triggered mechanical injector. The injection rate was 4 ml/s to a total injection volume of 40 ml of contrast agent followed by injection of 20 ml of contrast agent at 3 ml/s. Transverse scans were acquired in the helical mode with radiation parameters 120 kV and 300 mA, matrix size 512 x 512, field of view (FOV) 28-32 cm, slice thickness 1 mm, pitch 1.0, and isotropic voxel size 0.5 mm. The acquisition time was 11-16 s.

Imaging data were stored in digital imaging and communications in medicine (DICOM) format and subsequently analyzed with OsiriX imaging software (OsiriX Foundation, Geneva, Switzerland). Three-dimensional reconstruction of the data was performed to permit viewing of the anatomical area of interest. Settings for the three-dimensional reconstruction algorithm were established as follows: The database window of the program was opened to find the patient's two-dimensional computerized tomographic angiography images sequence. The imaging cluster was unpacked to the front window. 3D Volume Rendering option was selected to create three-dimensional volume rendered image after the opening of 2D/3D Reconstruction Tools from the dashboard. Following automatic opening of the next window including the volume rendered image graphics processing unit (GPU) engine was selected to render the image at the best resolution. If it was necessary to remove the artifact from the head fixation device, the Sculpt function could be selected to remove the artifact from the working window. The button for rotating around the focal point was selected among the Mouse button functions to rotate the images to view the region from a point perpendicular to the anatomic area of interest. The button for the zoom function could also be selected for magnification of the image. Then Window-Level section was selected to arrange the opacity of the image for maximal reconstruction of the vascular and/or bone structures. The Measurement button was selected to measure diameter, width, and length of the structures as well as to measure the distance between two different points.

## Results

To evaluate the presence or absence of intracranial aneurysms, the bilateral courses of the internal carotid artery at the foramen lacerum of 53 patients (26 male and 27 female) were evaluated with computerized tomographic angiography. The mean age of the patients was 57.92±9.7 years. Three-dimensional volume rendered neurovascular images based on the computerized tomographic angiography were evaluated to analyze the course of the internal carotid artery at the foramen lacerum and at the carotid sulcus on the sphenoid bone and processes petrolingualis.

The internal carotid artery enters into the skull via the carotid canal. The artery enters the canal through the carotid foramen located at the inferior aspect of the skull base. The internal carotid artery exits the carotid canal via the internal foramen located at the site of the foramen lacerum. The segment of the internal carotid artery located inside the carotid canal is called the petrous segment. The segment of the artery between the internal foramen of the carotid canal and the superior border of the petrolingual ligament is classified as the lacerum segment. The level of the petrolingual ligament is important in the determination of the segments of the internal carotid artery and posterolateral border of the cavernous sinus. The sites and bony marks of the petrolingual ligament attachments were evaluated using three-dimensional volume rendering technique.

The petrous part of the petrolingual process has a wider range of base in comparison with sphenoidal part. Processes petrolingualis with its petrous and sphenoidal parts incompletely cover the internal carotid artery at the end of the lacerum segment. This structure creates a bony skeleton for the petrolingual ligament (Figure a).

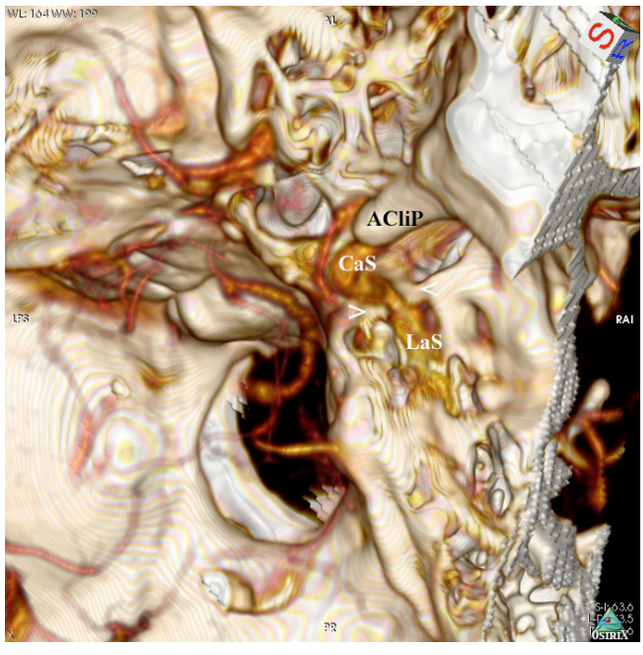


Figure a. The three-dimensional volume rendered images of the skull base in the superior aspect (ACliP: Anterior Clinoid Process, CaS: Carotid Segment, LaS: Lacerum Segment, White arrow: Processes petrolingualis).

## Discussion

The foramen lacerum is a generally triangular shaped bony foramen located between the sphenoid, apex of the petrous temporal, and basilar part of the occipital bones. The petrous portion of the internal carotid artery and carotid sympathetic nerve plexus pass through the carotid canal to reach the foramen lacerum. The lacerum segment of the internal carotid artery passes over the foramen lacerum to reach the cavernous sinus. The anatomic location of the foramen lacerum is perpendicular.

Recently, Bouthillier at al. [1] proposed a classification system that describes the entire internal carotid artery, uses a numerical scale in the direction of blood flow, and identifies the segments of the internal carotid artery according to the anatomy surrounding the internal carotid artery and the compartments through which it travels. According to this classification, the internal carotid artery has seven segments as follows: C1, cervical; C2, petrous; C3, lacerum; C4, cavernous; C5, clinoid; C6, ophthalmic; and C7, communicating. Ziyal et al. [12] and Rhoton [7] have also classified the segments of internal carotid artery without mentioning the lacerum segment.

The volume rendering technique may be used in the three-dimensional evaluation of some anatomical structures such as the internal carotid artery. Volume rendering technique is a group of modalities in the converting of two-dimensional images to the three-dimensional images [2,4,6]. The two-dimensional images acquired by computerized tomography and magnetic resonance imaging is used to create the volume rendered images [2,3,6]. Computerized tomographic angiography with its three-dimensional advantage is a commonly used diagnostic application to detect intracranial aneurysms. In the literature, the diagnostic sensitivity of computerized tomographic angiography has been reported between 70% and 96% depending on the size and location of the pathology [5,8,9,10,11]. A three-dimensional viewer provides modern rendering modes such as multiplanar reconstruction, surface rendering, volume rendering, and maximum intensity projection. In the present study, we used OsiriX software in the processing of DICOM images. This software may show the basal cerebral arteries and cervical segment of the internal carotid arteries together with the bone structures of the cranial base including the carotid canal.

The internal carotid artery passes through two foramen during its course through the carotid foramen. One of them is located in the external surface of the cranial base. The other foramen is located at the posterior border of the foramen lacerum. The internal carotid artery passes over the foramen lacerum to reach the cavernous sinus. The posterior border of the cavernous sinus is created by the petrolingual ligamentous structure. There are two bony marks in the determination of the posterior border of the cavernous sinus. Three-dimensional computerized tomographic evaluation may provide the visualization and determination of the bony structures such as the petrous and sphenoidal parts of processes petrolingualis in the evaluation of cases.

In this study, two anatomical bony landmarks were used to determine the internal carotid artery entrance to the cavernous sinus. These two processes are the processes petrolingualis. This process has two parts. One of them is located on the petrous part of the temporal bone. This part covers the internal carotid artery medially and superiorly. The other part is located on the sphenoid bone and named the pars sphenoidalis of processes petrolingualis.

The petrous segment of the internal carotid artery is covered with the bony structure of the temporal bone. The Latin term of the canal describes a tubular shape of passage with two openings. Like other canals, the carotid canal has two exits. The first opening is the entrance foramen of the internal carotid artery. This foramen faces the inferior external aspect of the cranial base. The second opening is located at the foramen lacerum. The internal carotid artery leaves the carotid canal via this foramen. This foramen faces the foramen lacerum and is referred to as the anterior carotid foramen. It is anatomically located in front of the other foramen, which is referred to as the inferior carotid foramen. The inferior carotid foramen is perpendicularly located at the cranial base. The anterior carotid foramen is vertically located at the base of the cranium facing the foramen lacerum. The anatomic location of the foramen lacerum is perpendicular. The carotid foramen has two portions inside the petrous portion of the temporal bone—the vertical part and the horizontal part. The vertical part follows the inferior carotid foramen. The vertical part turns sharply to the anterior direction until reaching the foramen lacerum via the anterior carotid foramen. The course of the horizontal part of the internal carotid artery has an antero-medial direction. It continues its course until reaching the anterior portion of the foramen lacerum. At this point, there is another semi-canal. The bridge

over the internal carotid artery creates the petrolingual ligament. This semi-canal continues with the carotid impression over the sphenoid wing.

The results of this study show that the three-dimensional volume rendering technique can be used in the evaluation of cranial base structures, including micro-vascular surgical anatomy. It is necessary to further evaluate the biomechanics, flow dynamics, and interaction with perivascular neural cranial base structures.

*Competing interests*

The authors declare that they have no competing interests.

**References**

1. Bouthillier A, Loveren HR, Keller JT: Segments of the internal carotid artery. Neurosurgery 1996;38:425-33.
2. Calboun PS, Kuszyk BS, Heath DG, Carley JC, Fishman EK. Three-dimensional volume rendering of spiral CT data: Theory and Method. RadioGraphics 1999;19(3):745-63.
3. Drebin RA, Carpenter L, Hanrahan P. Volume rendering. Comput Graph 1998;22:65-74.
4. Hwang SB, Kwak HS, Han YM, Chung GH. Detection of intracranial aneurysms using three dimensional multidetector-row CT angiography: Is bone subtraction necessary? European Journal of Radiology 2011;79:18-23.
5. Karamessini MT, Kagadis GC, Petsas T, Karnabatidis D, Konstantinou D, Sakellaropoulos GC et al. CT angiography with three-dimensional techniques for the early diagnosis of intracranial aneurysms: comparison with intraarterial DSA and the surgical findings. Eur J Radiol 2004;49:212-23.
6. Levoy M. Display of surfaces from volume data. IEEE Comput Graph Applicat 1988;8:29-37.
7. Rhoton AL Jr: The supratentorial arteries. Neurosurgery 2002;51(Suppl 1):53-120.
8. Teksam M, McKinney A, Casey S, et al., Multi-section CT angiography for detection of cerebral aneurysms. AJNR Am J Neuroradiol 2004;25:1485-92.
9. Tomandi BF, Hammen T, Klotz E, Ditt H, Stemper B, Lell M. Bone-subtraction CT angiography for the evaluation of intracranial aneurysms. AJNR Am J Neuroradiol 2006;27:55-9.
10. Waugh JR, Sachara N. Arteriographic complications in the DSA era. Radiology 1992;182:243-6.
11. White PM, Wardlaw JM, Easton V. Can noninvasive imaging accurately depict intracranial aneurysms? A systematic review. Radiology 2000;217:361-70.
12. Ziyal MI, Ozgen T, Sekhar LN, Ozcan OE, Cekirge S: Proposed classification of segments of the internal carotid artery: Anatomical study with angiographical interpretation. Neurol Med Chir (Tokyo) 2005;45:184-91.

***How to cite this article:***

Kuruoglu E. Processes Petrolingualis of the Foramen Lacerum and Relationship with the Internal Carotid Artery. J Clin Anal Med 2017;8(3): 198-201.